

3-1

서울성모병원

신승한, 정양국

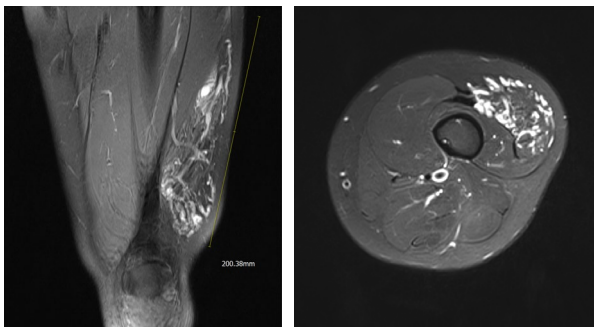
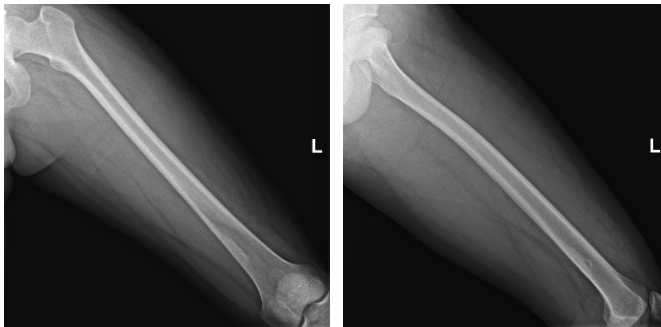
나이: 21

성별: M

주소(Chief Complaint): 좌측 원위 대퇴부 통증 및 부종

병력: 1년전부터 오래 서있으면 좌측 허벅지가 붓고 통증 생기며 덩어리가 커지는 것 같아 외래 내원함.

영상 검사:



토의 사항: 치료는?

3-2

성빈센트병원

주민욱

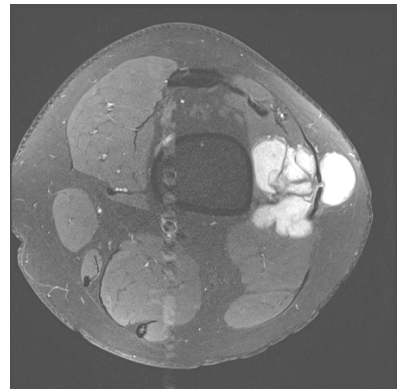
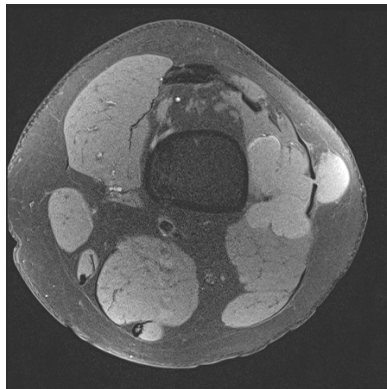
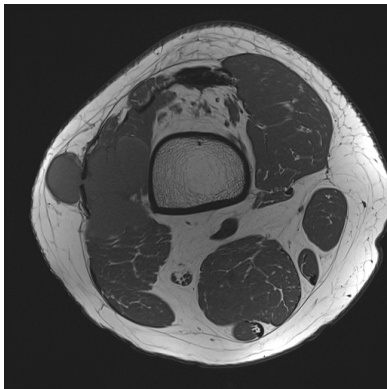
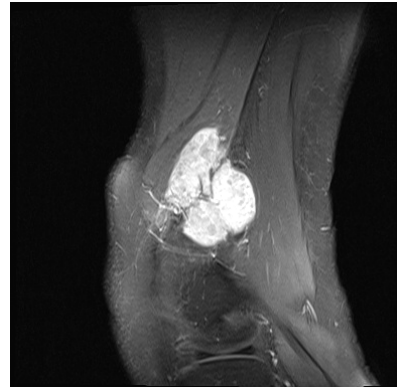
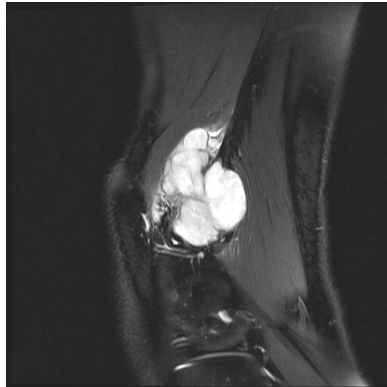
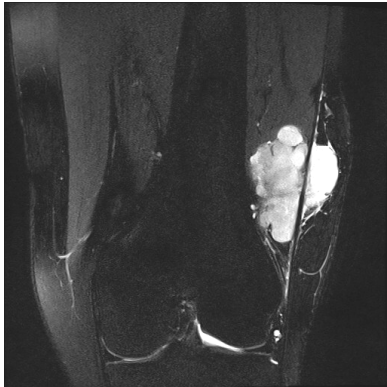
나이: 23

성별: 남

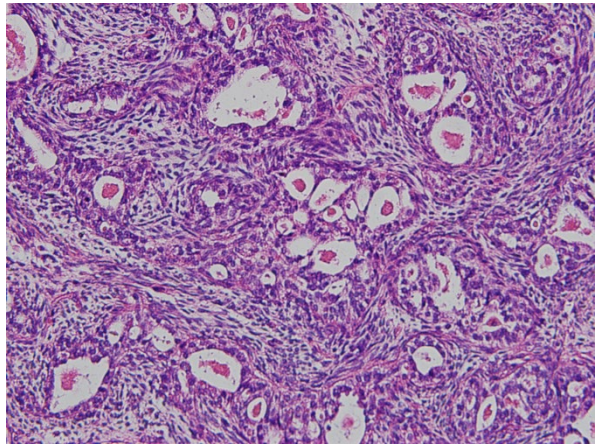
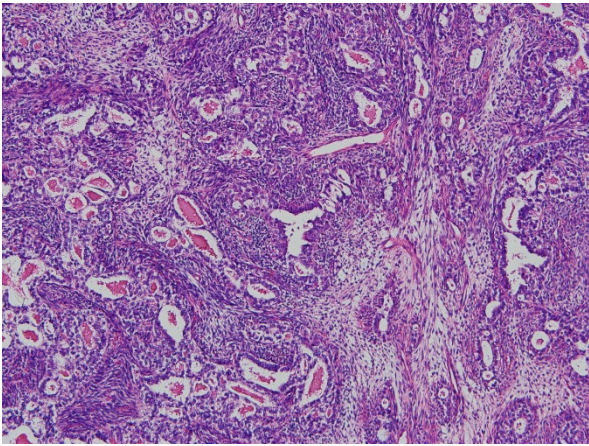
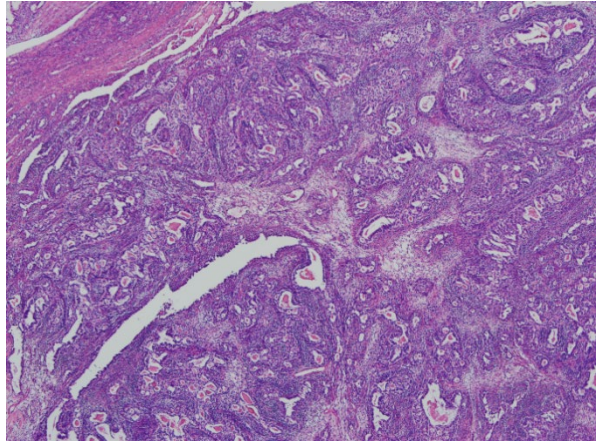
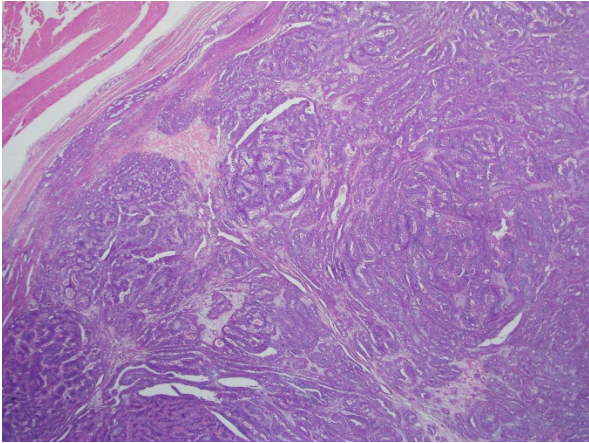
주소(Chief Complaint): 외상력 없이 3년 전부터 지속된 슬관절부 통증

병력: 상기 주소로 군병원에서 MRI 촬영 후 혈관종 의증으로 의뢰됨.

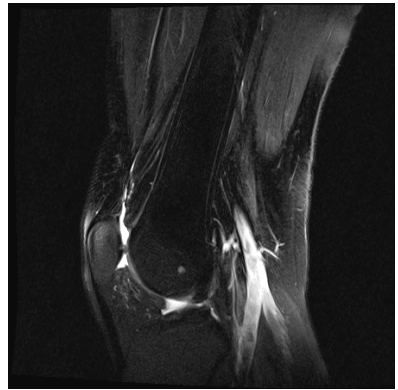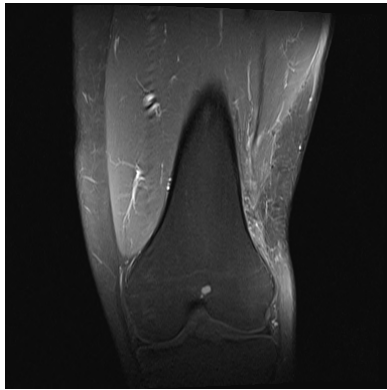
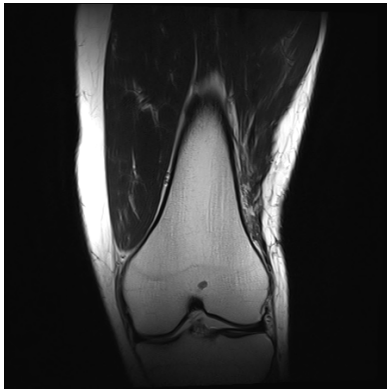
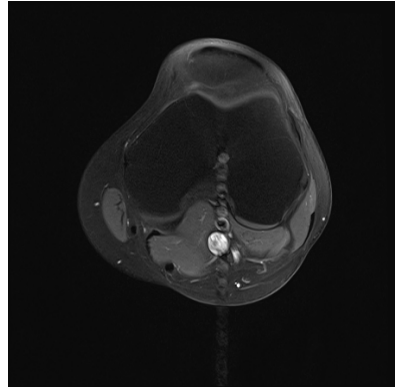
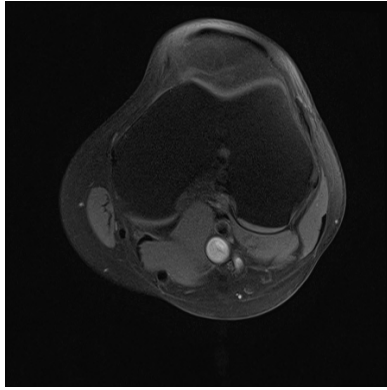
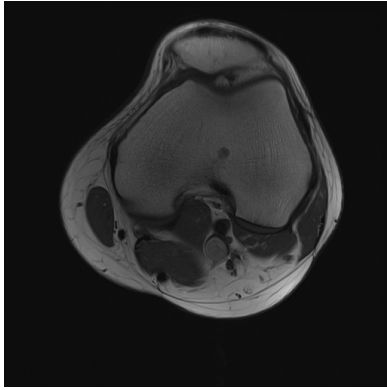
영상 검사:



조직 검사:



수술 후 3년 1개월



3-3

부천성모병원

이재영

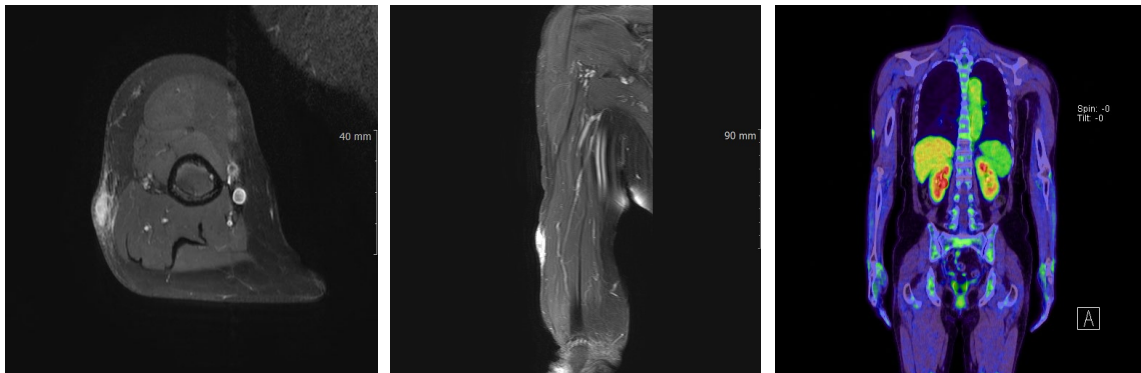나이: 59

성별: 여성

주소(Chief Complaint): Rt. Arm mass

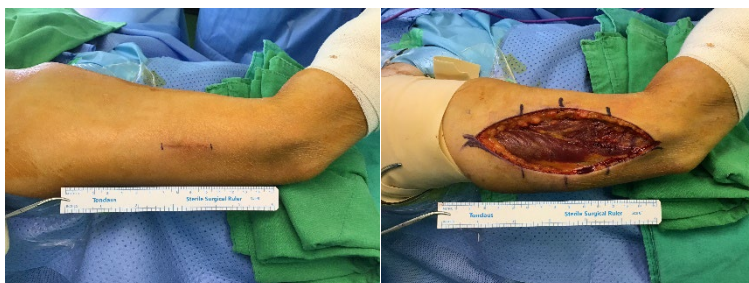병력: breast ca.

영상 검사:



조직 검사: Atypical fibrous histiocytoma

수술장 소견



토의 사항 : Pseudosarcomatous tumor

3-4

세브란스병원

김승현

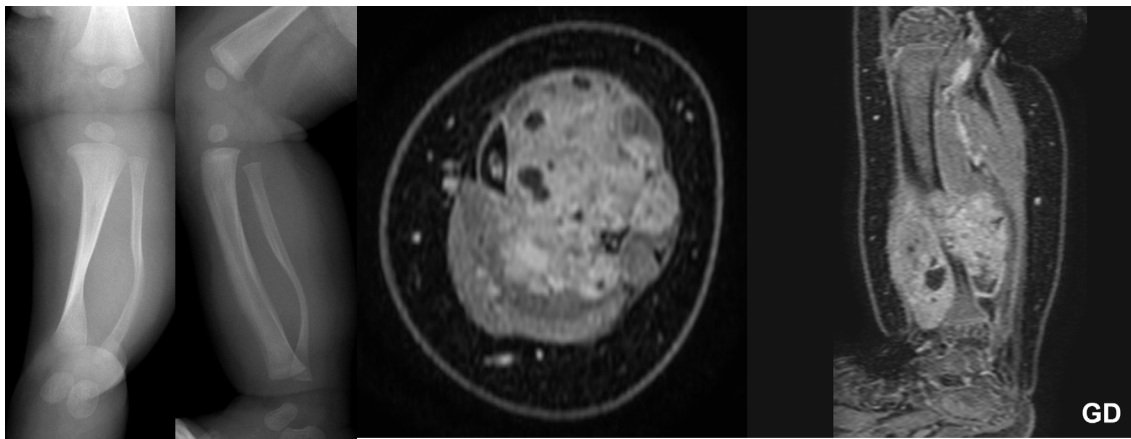
나이: 2M

성별: M

주소: 좌하지 종물

병력: NC

영상검사



조직검사: infantile fibrosarcoma

토의 사항: How to treat?

3-5

서울성모병원

김윤환, 정양국

나이: 47

성별: 여

주소(Chief Complaint): Mass on arm with numbness on Rt. hand for 2 months

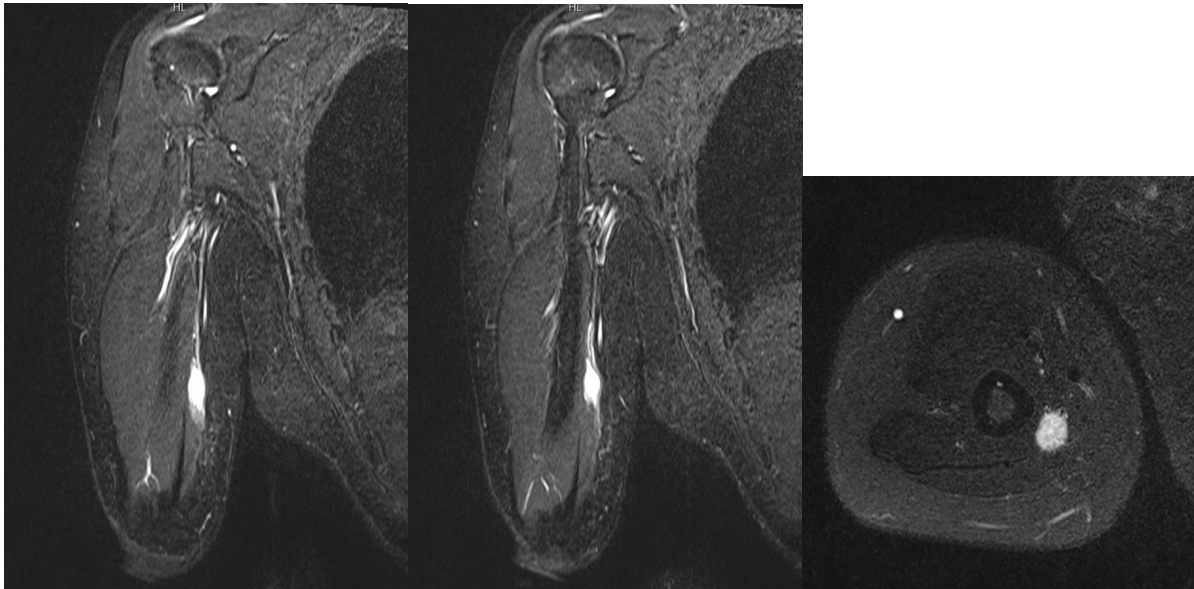
병력:

1) Thyroid cancer 로 Endoscopic lobectomy with CLND, Lt. & Wide excision, Rt.

2) Breast Ca로 Wide excision with SLNBx, Lt. (2020.09.04) 및 Total mastectomy with SLNBx, Lt.
(2020.12.30) 2회 수술 받음.

영상 검사 1:

Initial MRI (2022.01.05)



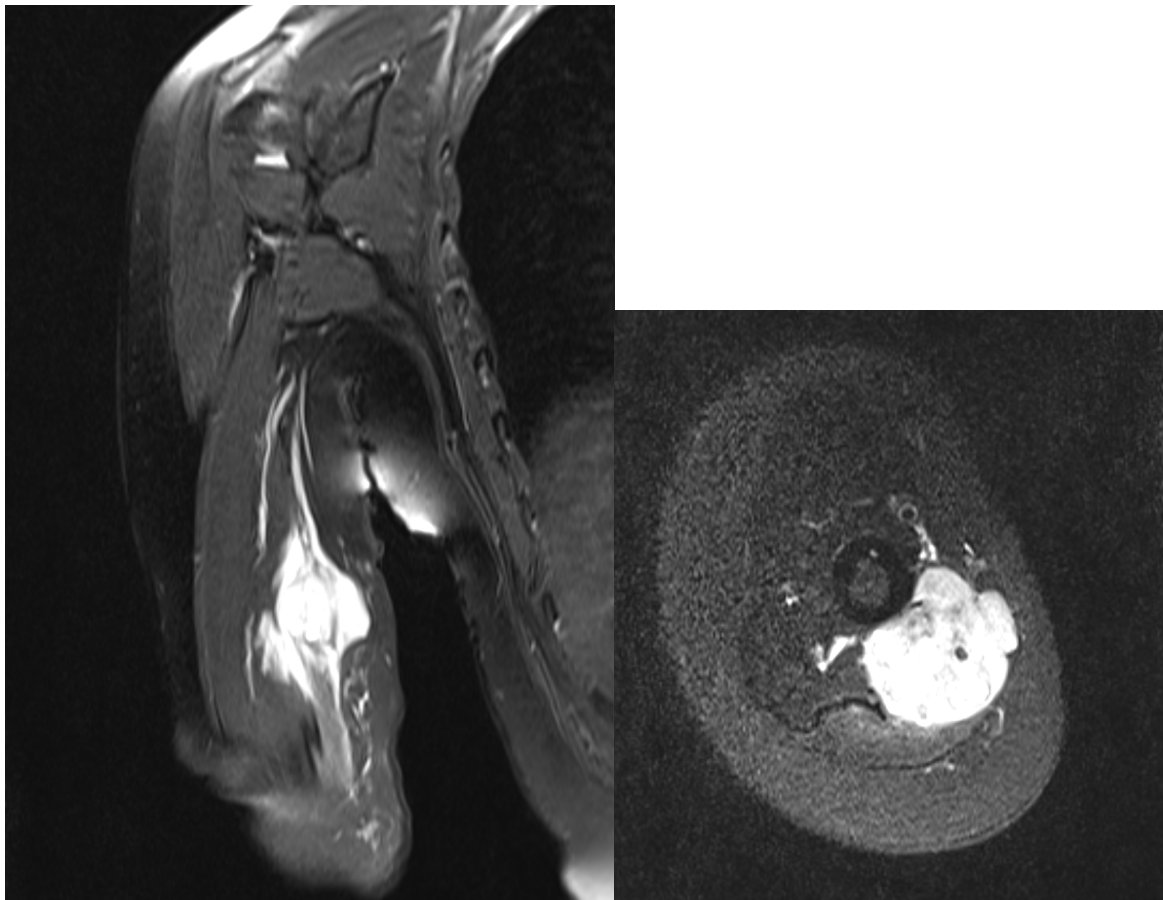
EMG (2022.03.31): Rt. ulnar neuropathy above the elbow

Discussion point 1

- 1) Your Dx. ?
- 2) Tx. plan ?

영상검사 2

F/U MRI (2022.04.14)



Discussion points 2

- 1) Your Dx. ?
- 2) How do you manage this lesion ?

3-6

부산대병원

김정일

나이: 58

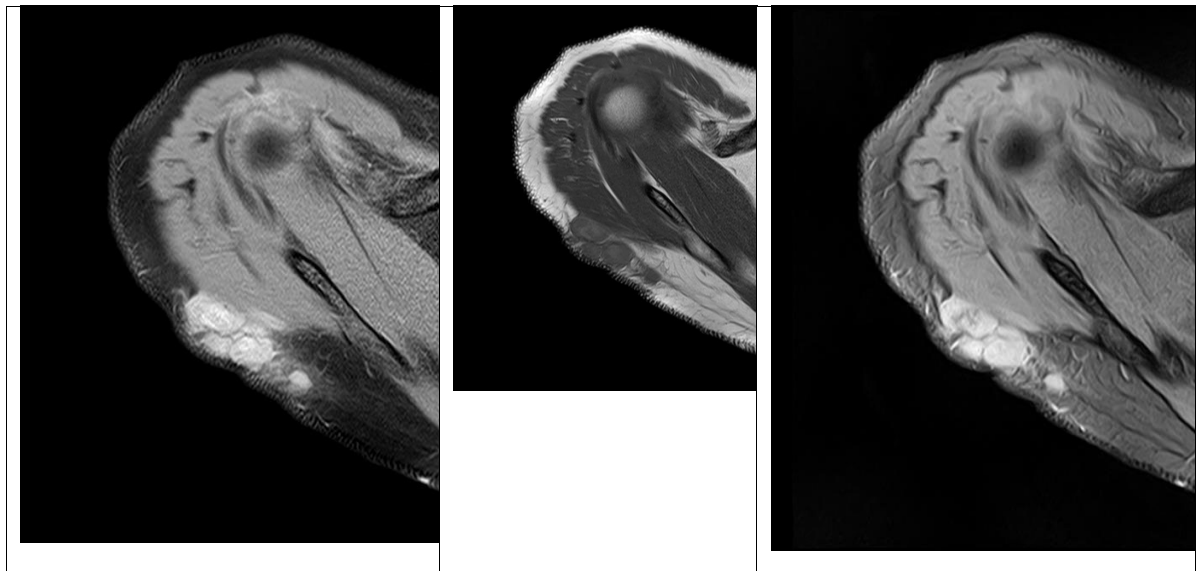
성별: F

주소(Chief Complaint) : 좌측 어깨 후방부 종물감.

병력: 1-2년 전부터 좌측 어깨 뒤쪽으로 만져지는 종물로 수술적 치료 필요하여 정형외과 진료 권유받고 2021-07-06 의뢰됨.

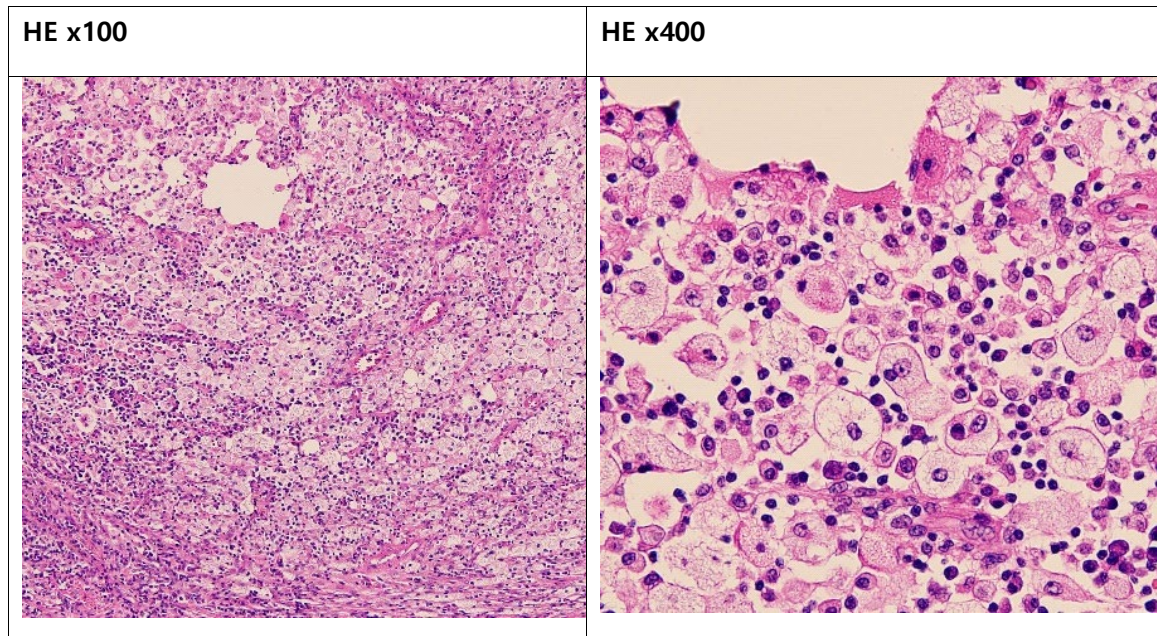
영상 검사:

2021.4.15 MR shoulder

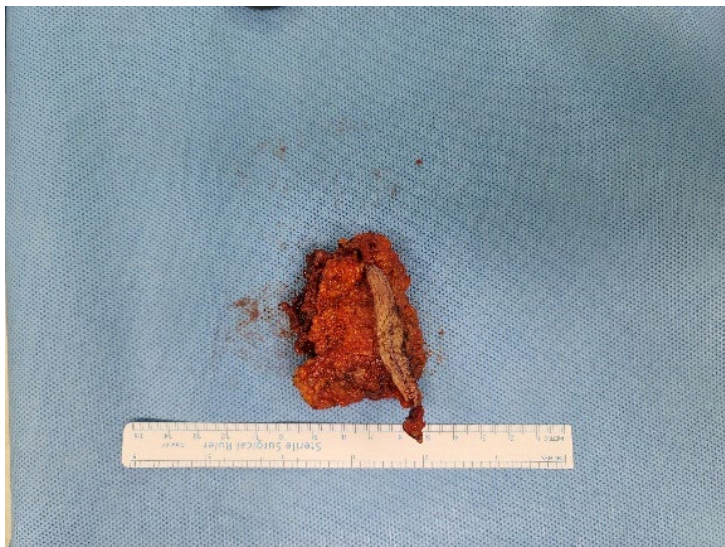


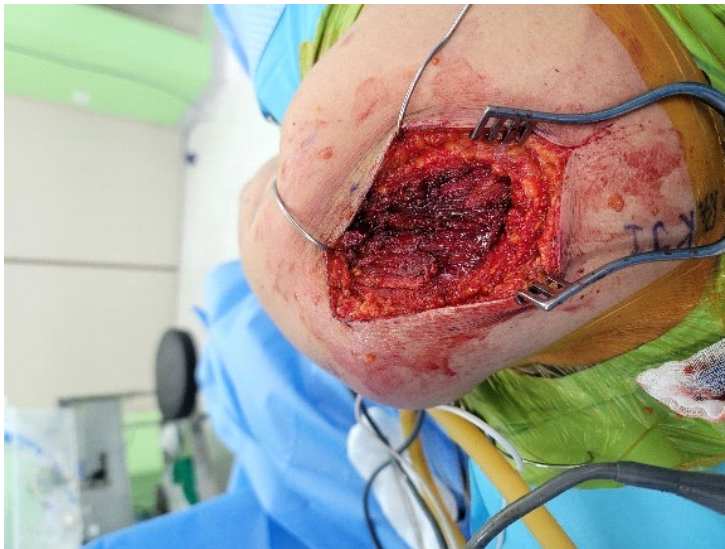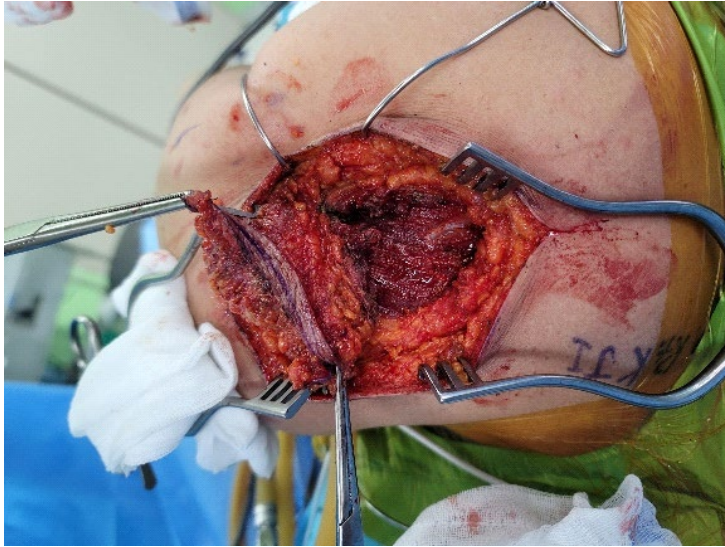
조직 검사:

2021.8.23 Skin, shoulder, right, excision :



수술장 소견





토의 사항: